

# THE OCULAR OUTLOOK



A Quarterly Publication for the Veterinary Community from Eye Care for Animals

## ULTRASONOGRAPHY IN VETERINARY OPHTHALMOLOGY



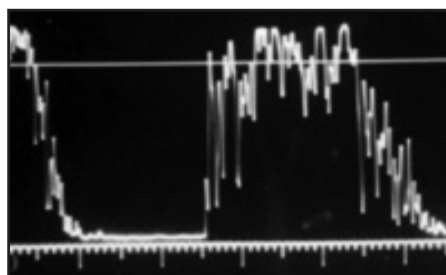
Jennifer A. Hyman, MA, VMD, DACVO  
Eye Care for Animals

Ultrasonography utilizes sound waves to examine objects and is widely used in the practice of medicine. Sonar, used by the military, was the original basis for medical ultrasound. It is non-invasive and does not harm the tissues of the eye. High frequency sound waves are emitted from a probe which then receives the echoes from the different tissues through which the sound waves traveled. The reflected echoes are displayed on a screen resulting in a picture.

The probes used in ophthalmology incorporate much higher frequency soundwaves than probes used in abdominal or cardiac ultrasonography. Frequency is

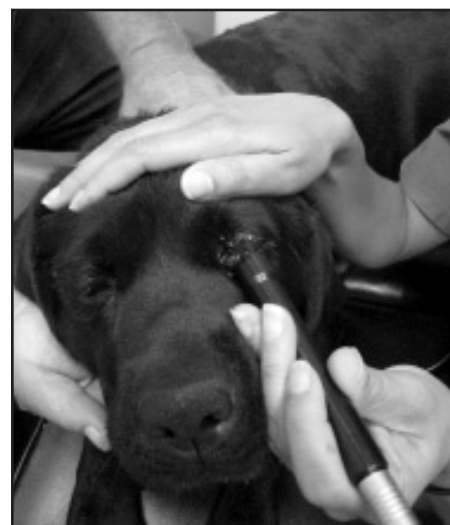measured in Hertz and is the number of cycles per second. Diagnostic ophthalmic ultrasonography probes utilize millions of cycles/second (megahertz).

Two different types of ultrasonography are used in ophthalmology; A (amplitude)-scan and B (brightness)-scan. In A-scan ultrasonography, a thin, parallel sound beam is emitted, which passes through the eye and images one small axis of tissue; the echoes of which are represented as spikes arising from a baseline. The stronger the echo, the higher the spike. In B-scan ultrasonography, an oscillating sound beam is emitted, passing through the eye and imaging a slice of tissue; the echoes of which are represented as a multitude of dots that together form an image on the screen. The stronger the echo, the brighter the dot.



*A-scan of a posterior segment tumor*

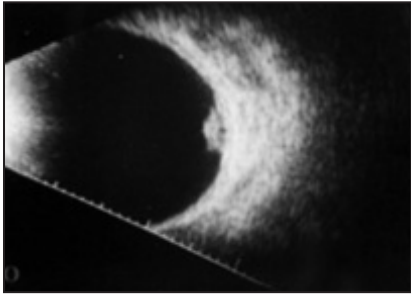
A-scan is commonly used to measure intraocular structures. 8MHz probes are used to differentiate intraocular



lesions while 10MHz probes are used to measure the length of the eye and intraocular structures. Measurement of the eye is called Biometry. Lastly, 20 MHz probes are needed for Pachymetry or the measurement of corneal thickness. A-scan is commonly used to calculate the strength of intraocular lens implant needed for cataract surgery in people. A-scan also yields objective information on abnormalities imaged with B-scan.

### INSIDE THIS ISSUE:

Scientific Article .....	Pg 1-2
What's New .....	Pg 3-4
CERF Corner .....	Pg 5
Memo to Managers.....	Pg 6

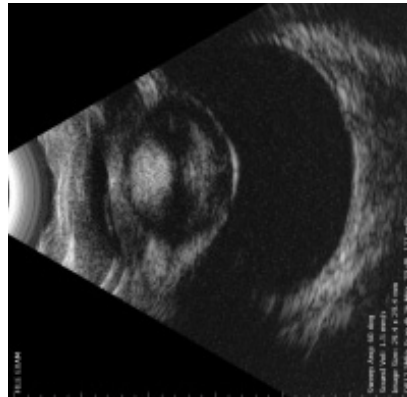

*B-scan of a posterior segment tumor*

B-scan ultrasonography is part of pre-cataract surgery testing. Usually the retina cannot be visualized prior to surgery so it is important to confirm that the retina is not detached as it is possible to have a positive ERG with a retinal detachment. Additionally, the vitreous, the posterior lens, and the lens capsule should be evaluated prior to surgery. A large posterior lens capsule tear might prevent placement of an intraocular lens or a posterior capsular tear may be associated with posterior displacement of the lens nucleus. Knowledge of either abnormality aids in pre-surgical planning.

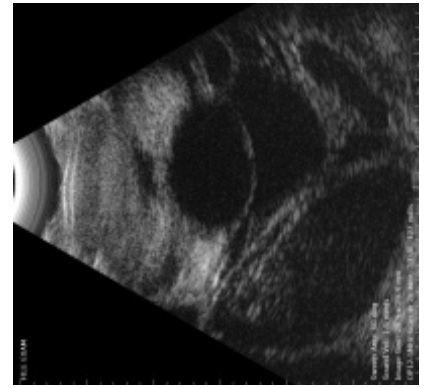
B-scan is also important when hyphema, lipid-laden aqueous or other conditions leading to an opaque ocular medium are present. For example, acute onset of hyphema might be due to a variety of causes, such as a

retinal tear, an intraocular tumor, or trauma. Ultrasonography may be used to diagnose the cause of acute hyphema and should be included in the diagnostic plan for evaluating an eye with hyphema or otherwise opaque media. B-scan is also important in evaluating retrobulbar abnormalities. Possible etiologies for exophthalmos include tumor, cyst, abscess, cellulitis, and others; ultrasound results may differentiate between these as well as establish a basis for further diagnostic imaging.



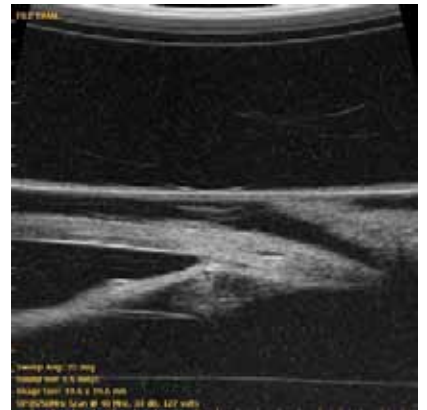*Intumescent Cataract*

High resolution ultrasound is the newest modality available in veterinary ophthalmology and yields information on the anterior segment. Different probes are needed to allow visualization of different depths in the eye. For instance, a 20 MHz probe allows



*Anterior segment Hyphema; Choroidal and Retinal Detachments*

visualization of the cornea to posterior lens, a 35 MHz probe has a functional view of the cornea to anterior lens, 50 MHz views the cornea to anterior lens also, and a 100 MHz the cornea alone. These very high frequency probes incorporate a water bath at the probe tip and allow very high resolution but have very shallow tissue penetration.



*Iris Mass*

Ultrasonography will aid in surgical planning via visualization and measurement of the specific intraocular mass. For example, knowing the depth of a corneal sequestrum and whether it is full or partial thickness in the cornea allows better surgical planning. The ability to measure the extent of an iris mass to give the owner more accurate surgical options is also invaluable.

## Editor's box

# Ocular Outlook

Editor: Sara Calvarese, DVM, DACVO  
 Managing Editor: Julie Gamarano

Eye Care for Animals welcomes your comments on the Ocular Outlook.  
 Please e-mail your feedback to [jgamarano@eyecareforanimals.com](mailto:jgamarano@eyecareforanimals.com)  
 or call Julie at (480) 424-3947 extension 111.

# WHAT'S NEW AT EYE CARE FOR ANIMALS?

## 2008 New Openings & Relocations

### **Annapolis, Maryland New Opening**

**January, 2008**

Located in the Chesapeake Veterinary Referral Center,  
808 Bestgate Road Annapolis, MD 21401

Monday – Friday 9am – 5pm and two Saturdays per month.

Please contact our office at 410-224-4470 to schedule an appointment.

### **St. Charles, Illinois Relocation**

**August 1, 2008**

2002 W. Main Street, Suite Q  
St. Charles, IL 60174

Monday-Friday 8:30am -4:30pm limited Saturday appointments available.

Please contact our office at 630-444-0393 to schedule an appointment.

### **Santa Fe, New Mexico New Opening**

**August 1, 2008**

Located in the Veterinary Emergency & Specialty Center of New Mexico,  
2001 Vivigen Way Santa Fe, NM 87505

Mondays and Fridays from 9am-4:30pm

Please contact our Albuquerque office at 866-697-3937 to schedule an appointment.

### **Pewaukee, Wisconsin New Opening**

**September 2, 2008**

21160 W. Capital Dr. Unit B Pewaukee, Wisconsin 53072

Monday – Friday from 8am – 5pm

Please contact us at 262-754-3550 to schedule an appointment.

### **Salt Lake City, Utah Relocation**

**September 10, 2008**

Located in the Veterinary Specialty Center of Utah  
1021 East 3300 South

Salt Lake City, Utah 84106

Please contact us at 801-942-3937 to schedule an appointments.

*These new locations allow us to continue providing your communities  
with state of the art medicine and compassionate care.*

## UPCOMING EYE CARE FOR ANIMALS CONTINUING EDUCATION LECTURES

### **Albuquerque, New Mexico**

#### **Continuing Education**

#### **A Weekend with the Specialists**

Topics: *Dentistry, Dermatology, Oncology, Ophthalmology, Surgery, Internal Medicine, Critical Care, Physical Therapy*

Location: Embassy Suites Hotel & Spa  
1000 Woodward Place North East,  
Albuquerque, New Mexico 87102

Date: August 23<sup>rd</sup> & 24<sup>th</sup>, 2008

Please contact Julie Gamarano for  
further information at 480-682-6911  
jgamarano@eyecareforanimals.com

### **Gilbert, Arizona**

#### **Continuing Education**

Lisa Felchle, DVM, DACVO

Topic: *Ocular Emergencies*

Location: Arizona Veterinary Specialists  
86 West Juniper Avenue, Gilbert, Arizona

Date: September 10, 2008

Time: 6:30pm – 7:30pm

Dinner will be provided

RSVP by August 15<sup>th</sup> at 480-635-1110 option #4  
dsmith@eyecareforanimals.com

Sponsored by: Pet & Mac's Pet Resort  
& Antech Diagnostics

### **Scottsdale, Arizona**

#### **Continuing Education**

Jennifer Urbanz, DVM, DACVO

Topic: *Advances in Glaucoma Therapy:  
A look at saving vision*

Location: TBA

Date: November 6, 2008

Dinner will be provided

RSVP by October 31, 2008 480-948-2362  
tperkins@eyecareforanimals.com

### **Gilbert, Arizona**

#### **Continuing Education**

Lynsey Smith, DVM

Topic: *Tonopen*

Location: Arizona Veterinary Specialists  
86 West Juniper Avenue, Gilbert, Arizona

Date: December 10, 2008

Time: 6:30pm – 7:30pm

Dinner will be provided

RSVP by December 3, 2008  
dsmith@eyecareforanimals.com

For more information on these and other upcoming events or questions related to marketing and public relations, please contact Julie Gamarano at [jgamarano@eyecareforanimals.com](mailto:jgamarano@eyecareforanimals.com).

## CERF CORNER



Christin Fahrner, DVM,  
MS, DACVO  
Eye Care for Animals

### Retinal Folds or Dysplasia

Patient evaluation for Canine Eye Registry Foundation (CERF) examinations includes evaluation of anterior segment structures including eyelids, third eyelid, conjunctival tissues, cornea, and intraocular structures including the iris and lens, typically with a slit lamp biomicroscope to improve magnification. The vitreous and fundus, which includes the retina, both tapetal and non-tapetal portions, the retinal vasculature, and the optic nerve are then typically evaluated using indirect ophthalmoscopy. The retina is scrutinized for abnormalities including abnormalities in its reflectivity, presence of hemorrhage, abnormalities in the retinal vasculature, elevations or depressions, and lesions including alterations in pigmentation, focal areas of increased or decreased reflectivity, or other abnormalities that could be present.

Retinal dysplasia and folds are abnormalities that can only be seen when using equipment to evaluate the structures of the posterior portion of the eye including direct or indirect ophthalmoscopy. Retinal dysplasia can occur in many breeds and is suspected to have a hereditary component in several purebred dogs including but not limited to various terrier breeds, Cavalier King Charles Spaniels, American and English Cocker Spaniels, Labrador and Golden Retrievers, and English Springer Spaniels. Dysplastic lesions could also be associated with other ocular or systemic abnormalities. The characteristic lesions associated with dysplasia are areas of abnormal or anomalous differentiation of the retina. Microscopically, these areas can be seen as folds in the neurosensory retina. Retinal dysplasia can be divided into simple folds that are linear, triangular, curved, or curvilinear line-like changes in the retina, focal or multifocal dysplasias that appear as dull streaks, dots or circles, geographic dysplasia that can be in an irregular large area and is often in the central portion of the tapetal fundus, or complete dysplastic lesions that can include retinal detachment.

Typically, the multifocal form of dysplasia is not considered to appreciably impact vision although the geographic or complete forms with retinal detachment can significantly affect vision with a large scotoma (blind spot), and could even result in blindness with retinal detachment. As patients are followed with time, dysplastic lesions do not tend to change significantly; however, in some young patients with the less severe and small forms such as retinal folds, the changes may become less obvious with time and the more severe larger lesions such as geographic dysplasia, can become more obvious over time. Retinal detachment with the most severe forms of dysplasia could increase the risk for hemorrhage, cataract, and secondary glaucoma.

**Check us out at [www.eyecareforanimals.com](http://www.eyecareforanimals.com)**



MEMO TO MANAGERS

“Attracting Clients and Growing Your Client Base”

Many would agree that the lifeblood of a successful business is its clients. There are some basic approaches to ensure a steady client base continues to grow and flourish.

1. Convert callers into new clients. The first point of contact a client has is usually with a member of the front-line team—the client care representative or receptionist. So when thinking about budgeting for marketing and advertising, allocate monies in the budget for training! Business managers go to great lengths to try and hire the most qualified, educated, knowledgeable, and friendly employees that they can. Investing in training for the front-line team is money well spent! Train the front-line on how to successfully convert callers into new clients.
2. Schedule an appointment. When clients (or potential clients) call to inquire about a procedure or price, use that opportunity to schedule an appointment. The chances of turning callers into new clients is much more successful if the front-line just asks to schedule an appointment. Studies have shown that many client care representatives or receptionists receive high marks with regards to being friendly and helpful - but only a very small percent of the front-line actually asks to schedule an appointment on inquiry related calls.
3. Ask clients to refer. Include those “special touches” to reinforce appreciation to clients, such as a simple thank you card or a follow-up phone call. Ask clients if they were pleased with the service they received. If yes, let them know that you would appreciate their referrals to family members and friends. Positive word of mouth is a persuasive form of advertising.
4. Follow up with callers and clients. Following up with clients (or potential clients) is a simple process and only takes a few minutes from the day. The best follow ups are the day after the appointment. And, when clients/patients are due for a recheck, calling the client along with sending a reminder note card can be a positive approach as well. Take the opportunity to see how the patient is doing, remind the client about the recheck, and schedule the appointment.



Karen Webster, MBA  
Chief Operations Officer  
Eye Care for Animals

We all have certain expectations regarding the service we receive from others. Encourage members of your team to go the extra mile to “wow” clients, to gain a comfort level with attracting new clients, and helping to grow the client base.

Gilbert, Arizona • Phoenix, Arizona • Scottsdale, Arizona • Tucson, Arizona • Corte Madera, California • Culver City, California  
Palm Desert, California • Pasadena, California • Santa Rosa, California • Tustin, California • Upland, California • Chicago, Illinois  
St. Charles, Illinois • Wheeling, Illinois • Overland Park, Kansas • Annapolis, Maryland • Las Vegas, Nevada • Albuquerque, New Mexico  
Santa Fe, New Mexico • Santa Teresa, New Mexico • Akron, Ohio • El Paso, Texas • Salt Lake City, Utah  
Sunset, Utah • Leesburg, Virginia • Springfield, Virginia • Pewaukee, Wisconsin

Seeing life through your pet's eyes

