

OCULAR Outlook

A QUARTERLY PUBLICATION FOR THE VETERINARY COMMUNITY FROM EYE CARE FOR ANIMALS

OPHTHALMIC STAINS TO DYE FOR



Jason Clark, DVM

Topically applied dyes are an important component of the eye examination and are used to assess integrity of the precorneal tear film, cornea, conjunctiva, and nasolacrimal system. The three stains used for this purpose are fluorescein, rose bengal, and lissamine green. Dyes also have research and experimental uses in veterinary and human ophthalmology that include measurement of intraocular pressure with certain types of tonometry, assessment of retinal diseases via angiography, and studies of aqueous humor and tear film dynamics. This article will focus on how these stains (dyes) are used clinically in veterinary ophthalmology.

Sodium fluorescein is the most commonly used dye and can be obtained as an impregnated strip or solution. It is also available in combination with anesthetic

(proparacaine) for simultaneous application to painful eyes. If using fluorescein alone, individual sterile strips are preferred to reduce the risk of contamination. The strip is moistened with sterile saline or rinse solution and a drop applied to the eye, or the strip is lightly touched to the superior bulbar conjunctiva. Care should be taken to avoid contacting the cornea with the strip, as small abrasions are possible. Fluorescein is water soluble and yellow to orange in color at acid pH. It turns green (fluoresces) at alkaline pH, and the fluorescence is maximized with blue light. Therefore, a strong rechargeable light source with a Finoff transilluminator and cobalt-blue light filter greatly facilitates examination. Cobalt-blue filters are inexpensive and fit snugly over the transilluminator tip. Fluorescein is useful in the following instances:

1. To detect corneal ulcers and erosions
2. To assess stability of the tear film
3. To assess patency of the nasolacrimal system
4. To detect leakage of a corneal wound or incision

Corneal ulcers are easily detected with fluorescein. Fluorescein is hydrophilic and not retained by the hydrophobic corneal epithelium, but it is readily retained by hydrophilic stroma. Additionally, fluorescein is not retained by Descemet's membrane. Superficial corneal ulcers stain bright green because of stromal retention. As an ulcer deepens, there is less stroma to retain the

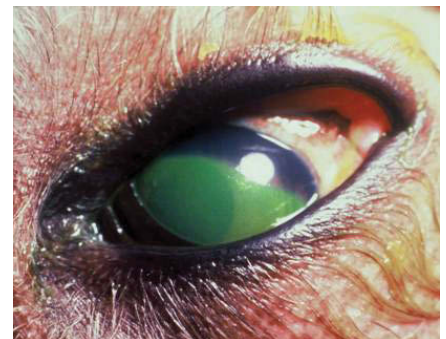

Figure 1

stain, so the fluorescence is less intense. By definition, an ulcer occurs when the epithelial basement membrane has been breached and exposes the stroma; corneal erosions represent partial thickness epithelial defects that do not extend below the basement membrane. The terms ulcer and erosion are often used interchangeably when describing superficial corneal lesions. However, fluorescein retention is less pronounced with erosions because permeability of the epithelium is merely altered. Even so, subtle epithelial lesions can be detected using magnification and cobalt-blue light. Three staining patterns are generally recognized:

(CONTINUED ON PAGE 2)

INSIDE THIS ISSUE

Upcoming Events	Pg3
Article Spotlight	Pg3
Message from the President	Pg4

Editor: Keith Collins, DVM, MS, DACVO
Managing Editor: Julie Gamarano

Eye Care for Animals welcomes your comments on the Ocular Outlook. Please e-mail your feedback to jgamarano@eyecareforanimals.com or call Julie at (480) 682-6911.

For electronic subscription please visit www.eyecareforanimals.com

Eye Care for Animals LOCATIONS

Avondale, Arizona
Gilbert, Arizona
Phoenix, Arizona
Scottsdale, Arizona
Tucson, Arizona
Chula Vista, California
Corte Madera, California
Culver City, California
Palm Desert, California
Pasadena, California
San Diego, California
Santa Rosa, California
Torrance, California
Tustin, California
Upland, California
Chicago, Illinois
St. Charles, Illinois
Wheeling, Illinois
Overland Park, Kansas
Wichita, Kansas
Lexington, Kentucky
Louisville, Kentucky
Annapolis, Maryland
Towson, Maryland
Lee's Summit, Missouri
Springfield, Missouri
Las Vegas, Nevada
Reno, Nevada
Albuquerque, New Mexico
Santa Fe, New Mexico
Akron, Ohio
Austin, Texas
El Paso, Texas
Houston, Texas
Round Rock, Texas
Orem, Utah
Salt Lake City, Utah
Sunset, Utah
Leesburg, Virginia
Pewaukee, Wisconsin

OPHTHALMIC STAINS TO DYE FOR

(CONTINUED FROM PAGE 1)

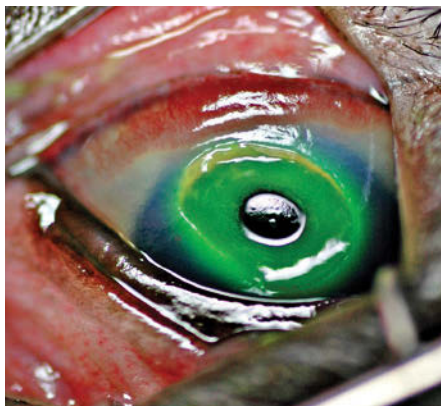

Figure 2

- a superficial or anterior stromal ulcer typically stains bright green (Figure 1). The intensity of fluorescence diminishes with depth of the ulcer.
- a crater defect that retains stain at the periphery and has a clear or glistening center suggests a descemetocoele (Figure 2).
- a crater defect that pools stain transiently, but from which stain is easily rinsed, suggests a prior deep ulcer that has re-epithelialized (called a facet). The center of the lesion is slightly hazy when compared with a descemetocoele (Figure 3).

Tear film break up time (TFBUT) is a test that utilizes fluorescein to assess the quality of the tear film. Abnormalities of tear mucin or lipid affect tear stability and will, therefore, alter the TFBUT. Pets with qualitative tear deficiency often have unexplained ocular disease that may include conjunctival hyperemia, and corneal opacity, vessels, and ulcers. If the cause is not clear and the Schirmer tear test normal, a TFBUT should be performed. To perform this test, concentrated fluorescein is applied to the eye, the lids held closed until ready for examination, and when opened the eye is immediately examined with magnification and cobalt light. The tear film initially appears as a homogenous green layer across the cornea but then begins to "break up" into small dark spots or patches. These patches are usually evident in normal dogs and cats after an average of 19-20 and 16-17 seconds, respectively. In eyes with

qualitative tear deficiency, the TFBUT is more rapid and typically less than 5-10 seconds.

Fluorescein can be used to assess patency of the nasolacrimal ducts, which is called the Jones test. The nasolacrimal ducts drain through the nares, so fluorescein applied to the eye(s) will usually exit the nares within 5-10 minutes. The presence of fluorescein at the nares indicates patency of that respective nasolacrimal duct (Figure 4). An absence of fluorescein is consistent with an obstructed tear duct but does not confirm it, as false-negative results are possible.

Fluorescein may be used to determine if aqueous humor is leaking from a corneal wound or descemetocoele. This is called the Siedel test. High concentrations of fluorescein (2% or greater) are used in the eye undiluted. Aqueous leakage from a corneal wound causes dilution of fluorescein and a change in fluorescence that is detected using magnification and a cobalt-blue filtered light.

Rose Bengal is retained by dead or devitalized corneal and conjunctival epithelium, the tear film, and at high doses by healthy tissues (Figure 5). It is beneficial for detection of subtle epithelial lesions such as dendritic corneal ulcers in cats with herpesvirus infection. It has also been advocated for early diagnosis of dry eye patients where the epithelial surface is

(CONTINUED ON PAGE 3)

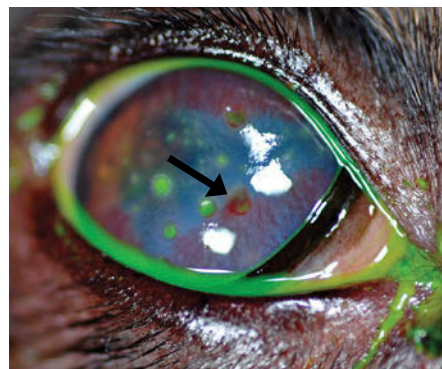


Figure 3. Arrow denotes corneal facet.

OPHTHALMIC STAINS TO DYE FOR

(CONTINUED FROM PAGE 2)

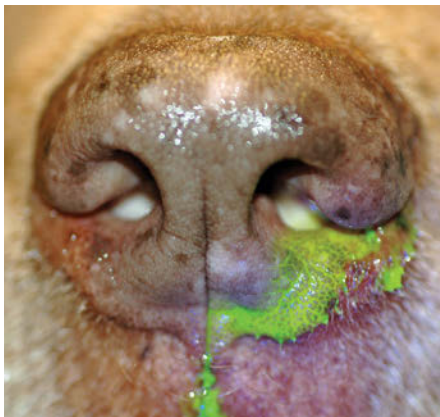


Figure 4

unhealthy but not ulcerated. It is available as an impregnated paper strip or in solution. This stain can be toxic to corneal epithelial cells and irritating to the patient. Therefore, use of a 0.5% or lower concentration is recommended. Rose Bengal and fluorescein may be administered at the same time if both are needed.

Lissamine green is more commonly used in Europe than in the U.S. and has staining properties similar to Rose Bengal. However, it does not appear to be toxic to epithelial cells and has been shown to only stain damaged epithelial cells. It too is useful for evaluating surface disorders and is less irritating to the patient than Rose Bengal.

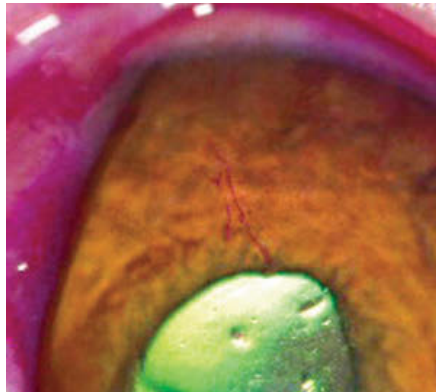

Figure 5

ARTICLE SPOTLIGHT

Editor's note: The spotlight is intended to provide practitioners with clinically relevant information from journals not available to most veterinarians. Old and new articles will be included and are selected by the reviewer. This first article was selected by the editor.



Keith Collins, DVM, MS, DACVO

Title: A cross-linked hyaluronan gel accelerates healing of corneal epithelial abrasion and alkali burn injuries in rabbits. *Vet Ophthalmol* 2010;13:144-150.

Summary: This study investigated the effects of a topically applied, chemically modified, and cross-linked hyaluronan preparation on corneal wound healing in rabbits. Corneal wounds were created by chemical burn or abrasion with a surgical blade. Enhanced healing was noted in both instances using the modified hyaluronan.

Comments: Hyaluronon has been known to facilitate corneal healing for more than a decade. The modified

hyaluronan preparation used in this study has recently been advocated for the treatment of corneal wounds in dogs and cats and is commercially available. However, the authors state that accelerated corneal wound healing observed in this study was equivalent to that reported in the literature for unmodified hyaluronan. Artificial tear preparations containing unmodified hyaluronon are readily available as over the counter products. Thus far, products containing unmodified hyaluronon have not been shown to be any less effective for corneal healing of dogs and cats than those with modified hyaluronan.

Upcoming EVENTS

March 20, 2012 - Louisville, KY
Ophthalmology and Dermatology
Demos and Jeopardy

March 27, 2012 - Las Vegas, NV
Ocular Surgical Wet Lab for the
General Practitioner - FULL

April 3, 2012 - Las Vegas, NV
Ocular Surgical Wet Lab for the
General Practitioner

April 12, 2012 - Tucson, AZ
Corneal Ophthalmology - SAVMA
Meeting

April 26, 2012 - West Houston, TX
Ocular Pharmacology

April 29, 2012 - Tustin, CA
Weekend with the Specialists

May 19, 2012 - Tempe, AZ
A Day with the Specialists

August 17-19, 2012 - Albuquerque, NM
Weekend with the Specialists

August 29, 2012 - Culver City, CA
Neuro-Ophthalmology: The Basics

For more information please
contact Julie Gamarano at
jgamarano@eyecareforanimals.com

TALKING WITH THE MEDIA—TIPS



Karen Webster, MBA
President & CEO, Eye Care for Animals

Do you welcome the opportunity to be interviewed by the media or do everything possible not to be in the lime light? There may be times when media opportunities present themselves where you can take advantage of gaining exposure for yourself and what you have to offer, or exposure for your Practice.

If the media called today where might you hold an interview? If on-premise consider an outside interview if noise levels are low, and stand next to your signage or some other eye-appealing background. If inside the facility it's recommended not to sit behind a desk, not stand in front of a plain white wall, or in an area with a lot of activity in the background.

What should you do before the media interviews you? A good starting point is to get your thoughts in order and write down a few important points you want to highlight. Always con-

sider the toughest questions you think you may be asked. Ask the media contact if you can have a list of questions in advance, or at least what the key topics of discussion will be before the interview. If the interview is for publication, ask if you will have the opportunity to review the piece in advance and comment back before it's published. Many times the interviewer will allow this. If time allows always ask if you can meet with the reporter in advance to review the major topics that will be discussed. This also provides an opportunity to get to know the reporter before the actual interview. Remember, you are in control of the interview and depending upon the questions asked you should be able to interject the key points you want to make.

The media is not the enemy. And, while some reporters may ask difficult or challenging questions, this is your chance to be heard. Respond in a

timely manner and refrain from making comments that are "off the record" as everything you say is eligible for front page. Refrain from saying "no comment" if you don't know the answer. Acknowledge that you don't have that answer but would be happy to find out and get back with the reporter (then follow up later). Simply try to be as relaxed as you can, remember you are in control, and take advantage of those great media opportunities when they present themselves whereby you, your team, or your Practice can gain exposure!

A QUARTERLY PUBLICATION FOR THE VETERINARY COMMUNITY FROM EYE CARE FOR ANIMALS

OCULAR *Outlook*

PRESORTED
STANDARD
U.S. POSTAGE
PAID
TUCSON, AZ
PERMIT NO. 414

