


OCULAR Outlook

A QUARTERLY PUBLICATION FOR THE VETERINARY COMMUNITY FROM EYE CARE FOR ANIMALS

SALIVA OR NOT?

Keratoconjunctivitis sicca (KCS or dry eye) is a disease that represents the best and worst of veterinary ophthalmology. Prior to the 1980's, conventional medical treatment of canine KCS involved any combination of topically applied artificial tears, antibiotics, corticosteroids, acetylcysteine (Mucomyst), and oral or topical pilocarpine. Pilocarpine was the only lacrimostimulant available and is not effective for most patients. So, the introduction of cyclosporine as a lacrimostimulant was a remarkable breakthrough. Cyclosporine treatment for dry eye was first proposed, studied, and developed by a veterinary ophthalmologist. Indeed, its use by veterinarians for treatment of KCS (i.e., Optimmune) preceded its use by physician ophthalmologists (i.e., Restasis) by fifteen years. Topical cyclosporine has improved comfort and maintained vision for countless pets, and it (or the closely related tacrolimus) remains the primary treatment for KCS. Developments in stem cell treatment and nanotechnology may offer hope for these patients in the future.



**Dr. Reuben Merideth,
DVM, DACVO**

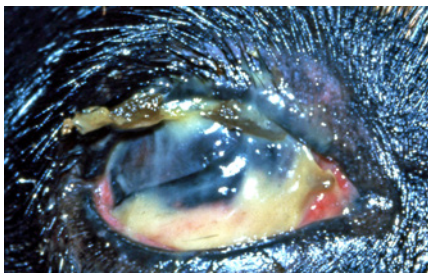
But what are the options for a dog that does not respond to dry eye treatment? Schirmer tear values for these pets often range from 0-5 mm/minute (normal >15 mm/minute), and they are at risk for chronic conjunctivitis, keratitis, ulceration, discomfort, and blindness (Figure 1). The onset of dry eye is usually gradual, and most affected dogs do not appear uncomfortable. For these pets, prolonged medical treatment to allow for a favorable response is acceptable. Weeks or months of lacrimostimulant treatment may be required before improved tear production is noted. An eye with low tear production can return to normal Schirmer tear values, but a suboptimal response is acceptable if symptoms subside. However, some patients with KCS suffer marked discomfort, blepharospasm, and ulcers for which no combination

of anti-inflammatory, analgesic, or lubricant treatment is effective in mitigating symptoms. These cases represent a small percentage of KCS patients, but they can be difficult to manage. KCS patients that are persistently in pain, suffer deep or recurrent ulcers, or at increased risk for vision loss should be considered for parotid duct transposition surgery.

Parotid duct transposition (PDT) was described as a treatment for KCS of people in the 1950's and for dogs in 1966. PDT surgery is occasionally performed in cats and has been described in horses, but it is most often performed in dogs. This procedure provides moisture to the eye via saliva and can be effective for select patients. Interest in PDT surgery waned with the advent of cyclosporine, but there has recently been renewed interest in its use for treatment of refractory KCS patients.

Prior to surgery, saliva production must be tested to determine if the pet is an acceptable candidate. Some KCS patients have concurrent dry mouth (xerostomia) that would preclude any benefit of surgery. Saliva production is easily tested

(CONTINUED ON PAGE 2)



**Figure 1:
Dog with severe KCS that is
unresponsive to treatment**

INSIDE THIS ISSUE

Upcoming Events	Pg. 3
Article Spotlight	Pg. 3
Message from the President	Pg. 4

OCULAR *Outlook*

Editor: Keith Collins, DVM, MS, DACVO
 Managing Editor: Debbie Brinkoetter

Eye Care for Animals welcomes your comments on the Ocular Outlook. Please e-mail your feedback to dbrinkoetter@eyecareforanimals.com or call Debbie at (480) 682-6911.

For electronic subscription please visit www.eyecareforanimals.com

Eye Care for Animals
LOCATIONS

- Avondale, Arizona
- East Tucson, Arizona
- Gilbert, Arizona
- Phoenix, Arizona
- Scottsdale, Arizona
- South Scottsdale, Arizona
- Tucson, Arizona
- Chula Vista, California
- Corte Madera, California
- Culver City, California
- Palm Desert, California
- Pasadena, California
- San Diego, California
- Santa Rosa, California
- Torrance, California
- Tustin, California
- Upland, California
- Woodland Hills, California
- Norwalk, Connecticut
- Chicago, Illinois
- St. Charles, Illinois
- Wheeling, Illinois
- Mission, Kansas
- Overland Park, Kansas
- Wichita, Kansas
- Lexington, Kentucky
- Louisville, Kentucky
- Annapolis, Maryland
- Towson, Maryland
- Lee's Summit, Missouri
- Springfield, Missouri
- Las Vegas, Nevada
- Reno, Nevada
- Albuquerque, New Mexico
- Santa Fe, New Mexico
- Akron, Ohio
- Warwick, Rhode Island
- Austin, Texas
- El Paso, Texas
- Houston, Texas
- Round Rock, Texas
- Salt Lake City, Utah
- Sunset, Utah
- Leesburg, Virginia
- Pewaukee, Wisconsin

SALIVA OR NOT? (CONTINUED FROM PAGE 1)

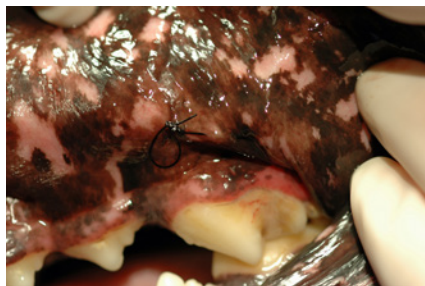


Figure 2:
Parotid papilla after it has been cannulated for surgery

by offering the pet a small treat or applying an agent to the tongue to stimulate salivation. Atropine is effective for this purpose. Atropine will decrease saliva production after systemic administration, but it is also bitter tasting and stimulates salivation when applied directly to the tongue. It is best applied by placing a drop of atropine on a cotton-tipped swab and then touching the swab to the tongue; this limits systemic absorption of the drug. If saliva production is normal, it should be easily seen exiting the papilla with the lip elevated.

Surgery requires dissection of the parotid papilla from the oral cavity via an open or closed approach. The open approach utilizes a facial incision to enhance surgical exposure during dissection. The closed approach is performed entirely from an oral mucosal incision. There are advantages and disadvantages of each approach. The duct is better visualized with an open approach, but the facial incision required increases surgical trauma, time, and the risk of seroma. The open approach is classically

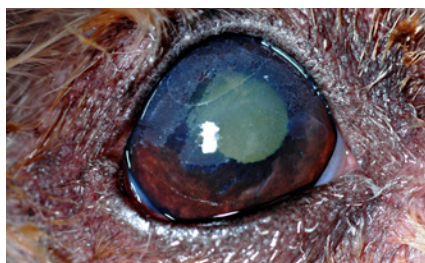


Figure 3: Mineral deposits on a dog's eye after PDT surgery. The diagonally clear area on the temporal cornea is where deposits were removed immediately prior to the photograph.

described, but many ophthalmologists now prefer the closed approach. With both approaches, the duct (and papilla) is first cannulated with suture to facilitate visualization during dissection (Figure 2). The papilla is located in the oral mucosa opposite the upper fourth premolar tooth. An incision is made to free the papilla from mucosa, and dissection of the duct extends caudally until it is sufficiently freed to reach the eye. A small incision is then made in the ventrolateral conjunctival fornix, and the papilla is trimmed and secured with 6-0 or 7-0 absorbable suture. The oral mucosal and facial wounds (if applicable) are closed in a routine manner. The operated eye often appears moist in the immediate postoperative period.

Complications after surgery can be short term and easily resolved or long term requiring intermittent or chronic treatment. Immediately after surgery complications may include corneal ulcers from conjunctival sutures, oral or facial wound dehiscence, seroma, and lower lid entropion secondary to the transposed papilla. Long-term complications include mineral deposits that accumulate on the cornea and eyelids, chronic epiphora and facial moisture, blepharitis, and periocular dermatitis. Partial ligation of the duct can be performed for dogs where moisture is excessive and problematic. Inadequate cleaning, the higher mineral content of saliva, and altered bacterial flora associated with saliva account for most of these problems. Proposed remedies to reduce mineral accumulation include oral acidifiers (e.g., methionine or vitamin C) to alter saliva pH, oral powdered buttermilk (mechanism not clear), topically applied calcium chelators (e.g., EDTA and acetylcysteine), and dietary management. Hill's prescription t/d diet may be effective, but data is limited. In one retrospective study of dogs after PDT surgery (Rhodes M, et al. *Vet Ophthalmol* 2012;15:4:213-222), the success of surgery was 92%, but the complication rate was 50%. Most complications were managed medically. Approximately

(CONTINUED ON PAGE 3)

ARTICLE SPOTLIGHT

Editor's note: The spotlight is intended to provide practitioners with clinically relevant information from journals not available to most veterinarians. Old and new articles are included and are selected by the reviewer. This article was provided by Dr. Amy Thompson-Hom.



**Dr. Amy Thompson-Hom,
DVM, DACVO**

Title: Canine Neurogenic Keratoconjunctivitis Sicca: 11 cases (2006–2010). *Vet Ophthalmol* 2012;15(4): 288–290

Summary: This is a retrospective study of eleven dogs with neurogenic keratoconjunctivitis sicca (KCS) and ipsilateral dry nose (exeromycetaria). Most cases were idiopathic, and two were the result of trauma. Numbers were small, but there was no apparent breed predilection, and middle-aged female dogs were most commonly affected. All dogs received pilocarpine at a starting dose of one drop of 1-2% solution per 10 kg body weight in the food twice daily.

Comments: There are multiple causes of KCS (dry eye), but most canine cases are due to immune-mediated disease directed toward the lacrimal glands. Neurogenic KCS occurs with loss of parasympathetic efferent innervation to the tear glands. Depending on the location of the lesion, other neurologic signs may be present; however, ipsilateral dry mucous membranes and dried exudate in the naris is classically described. Because of denervation hypersensitivity, tear production of affected eyes may improve with cholinergic treatment.

Pilocarpine is a cholinergic drug, and this is the rationale for its use in the treatment of neurogenic KCS. Oral pilocarpine at the aforementioned dose, or topically applied 0.1% solution have been advocated for treatment of KCS. Adverse systemic effects (vomiting, diarrhea, hypersalivation, etc.) may limit its oral use, and pets should be monitored accordingly. Topically applied pilocarpine may be irritating to the eye. Neither is likely to improve tear production in non-neurogenic patients.

Conclusion: Lacrimostimulants such as cyclosporine and tacrolimus are less likely to be of benefit in the treatment of neurogenic KCS. There has long been debate about the efficacy of pilocarpine for treatment of canine KCS. However, this study supports the efficacy of orally administered pilocarpine in dogs specifically having neurogenic KCS. In five of ten dogs, the signs of KCS resolved and pilocarpine was discontinued after a mean treatment time of 125 days. Clinical signs improved in the remaining dogs according to owners or referring veterinarians.

Upcoming EVENTS

August 3-4, 2013
Albuquerque, NM
Weekend With the Specialists

For more information please contact Marketing at marketing@eyecareforanimals.com

Congratulations FOR COMPLETION OF RESIDENCY!

Dustin Dees, DVM
Kevin Fritz, DVM
Annora Sheehan Gaerig, DVM

Welcome FOUR NEW RESIDENTS

Clinton Doering, PhD, DVM
Kimberly Hsu, DVM
Pamela Ko, DVM
Francesca Venturi, DVM

SALIVA OR NOT? (CONTINUED FROM PAGE 2)

33% of patients required continued topical treatments, but owner satisfaction was estimated at almost 90%.

PDT is not appropriate for every unresponsive KCS patient and may not eliminate the need for topical treatments. Diligent cleaning or other treatment measures may be required

to minimize mineral accumulation and control infection, and the client should be advised accordingly. Complications are common but can usually be managed effectively, and owner satisfaction is reasonably high. For all of its faults, PDT remains a viable option for treatment of severe dry eye.

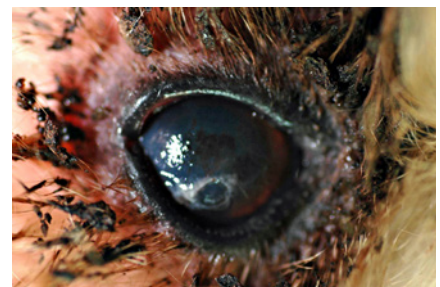

Figure 4: Excessive periocular moisture and blepharitis from inadequate cleaning.

“INSPIRED BY BLIND MOTIVATIONAL SPEAKER, TOM SULLIVAN”



Karen Webster, MBA
President & CEO, Eye Care for Animals

In April, the Eye Care for Animals (ECFA) doctor team was honored to spend time with blind motivational speaker, Tom Sullivan. Tom was blinded at birth by retrolental fibroplasia, now known as retinopathy of prematurity; however, he has not let his blindness stand in the way of his many successes and accomplishments. Tom is a 2-time Emmy award nominee, worked as a special correspondent for Good Morning America, has had more than 60 appearances on the Tonight Show, and is a Grammy-nominated recording artist—just to name a few! Tom reminds us of more than 36 million blind persons world-wide, and how important veterinary ophthalmology is to him and so many others who have impaired sight or lost vision and need their guide dog partners to be their set of eyes.

Before introducing Tom to our doctor team, I thought to myself, what would be the top 3 or 4 things I would want Tom Sullivan to know about his audience of veterinary ophthalmologists. That was very easy to answer, as ECFA has **an amazing group of scientists** who have dedicated all of their adult lives to the profession of veterinary ophthalmology. That in the past twelve months alone our doctor team has authored more than 20 scientific articles and abstracts based upon their dedication to ophthalmic research, has seen more than 55,000 patient appointments and completed thousands of surgical procedures to keep their patients visual and maintain the ocular health of their patients' eyes. I was also proud for Tom to know that ECFA has always provided 100% discount on services

to all active and working “Guide Dog for the Blind” patients because we know how important it is for our patients to be the set of eyes for their visually impaired owners. Meeting Baron, Tom’s guide dog partner, and hearing Tom’s inspirational story and how critical it is for guide dogs to be the set of eyes for millions of blind persons, was incredibly touching. I close with showing appreciation to our doctor team for their years of training in veterinary ophthalmology, their research, and their dedication and commitment to this profession. *Thank you ECFA Doctor Team!*

A QUARTERLY PUBLICATION FOR THE VETERINARY COMMUNITY FROM EYE CARE FOR ANIMALS

OCULAR AR *Outlook*

RESORTED
STANDARD
US POSTAGE
PAID
TUCSON, AZ
PERMIT #414

