

Feline Corneal Sequestra



B. Keith Collins, DVM, MS, DACVO
Eye Care for Animals

Corneal sequestrum is a relatively common but enigmatic condition of the feline eye. Sequestra have been reported in the dog and horse, but as a recognized clinical entity, they are unique to the cat. The typical clinical appearance is a unilateral, dark, circumscribed or elliptical, plaque in the central cornea. However, sequestra can be bilateral and affect the paracentral or peripheral cornea, and the color can vary from a subtle amber to brown or black. Cats of any

age can be affected, and there is no sex predilection. The size and rate of sequestra formation is variable. Persian, colorpoint, and pure-breed cats are predisposed, but any breed can be affected. Clinical diagnosis is straightforward, as there are few conditions that resemble sequestra. The differential diagnoses should include corneal pigment, corneal foreign body, and melanocytic tumors (i.e., limbal melanoma), but these conditions are uncommon in cats.

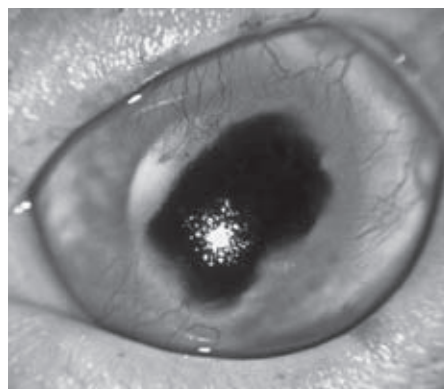


Figure 1: Preoperative appearance of a corneal sequestrum

The pathogenesis of corneal sequestra is uncertain, but

corneal insult or injury of some form appears to be a common factor. Most sequestra encountered by the author have been preceded by corneal ulceration. Experience suggests that the probability of sequestra formation increases with duration of the ulcer, so prompt healing of the ulcer is important. Infection with feline herpesvirus type-1 (FHV-1) is the most common cause of corneal ulcers in cats, so it is not surprising that FHV-1 has been implicated in the pathogenesis of sequestra. Herpesvirus has been identified in sequestra removed by keratectomy. Even so, a direct causative effect of FHV-1 has not been

(continued on page 2)

INSIDE THIS ISSUE:

Scientific Article.....	Pg 1-3
News & Events.....	Pg 4
CERF Corner.....	Pg 5
Memo to Managers.....	Pg 6

established, and prior studies are inconclusive. Eyelid abnormalities (e.g., entropion, aberrant hairs, etc.) that cause keratitis or ulceration may result in sequestrum formation. In such instances, the sequestrum is usually in proximity to the lid abnormality. The predisposition of certain breeds to develop sequestra may have a direct genetic basis, or it could simply be related to conformation. Persian and Himalayan cats may be at greater risk because of their brachycephalic conformation, prominent globes, and lagophthalmos. One study demonstrated decreased corneal sensation in brachycephalic cats. Such characteristics of brachycephalic cats seem plausible contributing factors to sequestrum formation.

Histologic evaluation of sequestra reveals loss of corneal epithelium

and stromal necrosis. Inflammatory cells and blood vessels are often present in underlying and adjacent cornea but do not typically invade the sequestrum. Symptoms of affected cats include lacrimation, variable corneal opacity, ulceration, vessels, and blepharospasm. Some cats are asymptomatic except for the sequestrum. Ophthalmologists have long suspected the corneal discoloration results from stromal deposition of an ingredient unique to feline tears. Concurrent discoloration of the tears and eyelid margins is common and supportive of this notion. Contact lenses used in the treatment of feline ulcers can become discolored, as have synthetic grafting materials used to treat deep ulcers. An occasional dark conjunctival plaque, or meibomian gland filled with dark material, may also be noted. Optical

microscopic evaluation of sequestra suggests the dark coloration is melanin.

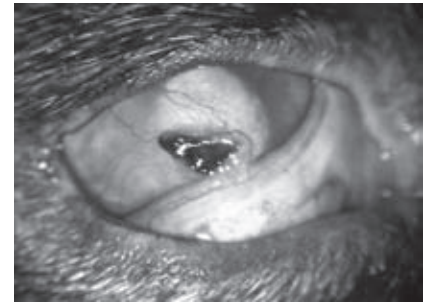


Figure 2: Sequestrum of the superficial cornea almost ready to slough

Some sequestra can be managed medically, but many require surgery. There are advantages and disadvantages to both approaches, and client education is important. The cat's level of discomfort may dictate the course of action. Some cats are exquisitely painful and remain so unless surgery is performed. A medical approach is acceptable in instances where the pet appears comfortable and the sequestrum affects the superficial cornea. However, treatment is likely to be prolonged. Sequestra can exteriorize and slough from the corneal surface, but many months or years are usually required for this to occur. Alternatively, the sequestrum can progress deeper in the cornea. Vascularization and scarring of previously normal cornea is often more pronounced in protracted

Editor's box

Ocular Outlook

Editor: Sara Calvarese, DVM, DACVO
Managing Editor: Julie Gamarano

Eye Care for Animals welcomes your comments on the Ocular Outlook.
Please e-mail your feedback to jgamarano@eyecareforanimals.com
or call Julie at (480) 682-6911.

For electronic subscription please visit www.eyecareforanimals.com

cases. Globe rupture is possible but uncommon.

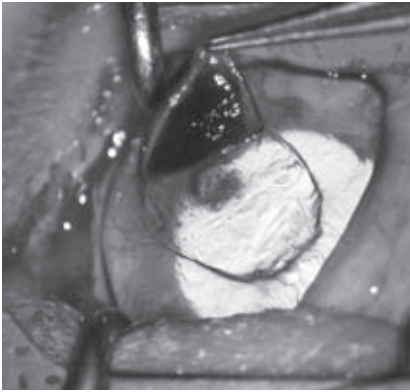


Figure 3: Lamellar keratectomy of the eye in Figure 1. Note the deeper area of discoloration that required additional dissection for removal.

Topical treatments usually include antibiotic, artificial tear, and antiviral preparations. An antibiotic solution or ointment is appropriate for initial treatment and after surgery, but continuous antibiotic treatment may not be appropriate. Artificial tear solution, gel, or ointment should be considered for long-term medical management after active infection is resolved. Such preparations may soothe the eye and promote eventual loosening and extrusion of the sequestrum. Empiric antiviral treatment may also be appropriate. Antiviral treatment will not affect the sequestrum, per se, but may improve comfort in sequestra eyes with concurrent FHV-1 infection. Oral

anti-inflammatory (e.g., Metacam) and analgesic (e.g., buprenorphine) medications may be appropriate depending on concurrent inflammation and degree of patient discomfort, respectively.

Surgery is the most expeditious way to resolve sequestra but can be technically challenging. Recurrence is possible, and clients should be advised accordingly. The recurrence rate can approach 20%, and recurrence is most likely if sequestra are incompletely removed. Most sequestra can be removed by lamellar keratectomy, but penetrating keratoplasty is sometimes required. Sequestra confined to the superficial cornea can be removed by keratectomy alone. Those that extend to Descemet's membrane or penetrate the eye may require penetrating keratoplasty. For sequestra that involve the deep corneal layers, a graft procedure is required to provide structural support and facilitate healing. There is controversy regarding the necessity for a graft procedure after removal of a superficial sequestrum. Graft procedures have

been postulated to reduce the rate of recurrence, and the author's personal experience supports this contention. However, results of one study demonstrated no significant difference in recurrence rate in eyes that received grafts and those that did not. Various types of conjunctival grafts, or corneconjunctival transposition, are the most common graft procedures performed. The exact procedure selected will depend on size and depth of the sequestrum, and skills and preferences of the surgeon.

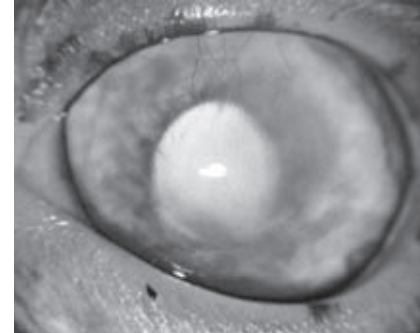
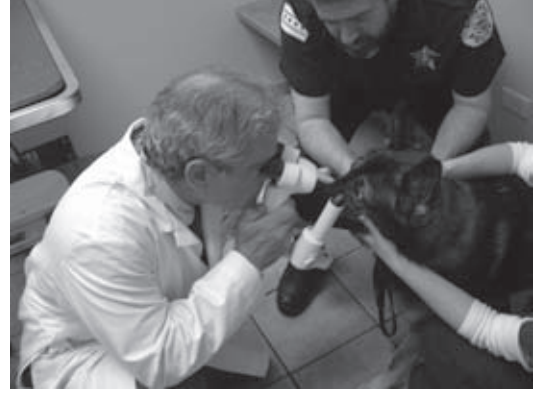

Figure 4: Two month postoperative appearance of eye in Figures 1 and 3. Surgical glue was used for structural support after keratectomy.

WHAT'S NEW AT EYE CARE FOR ANIMALS?



Sara Calvarese, DVM, DACVO was honored for her outstanding contributions to the field of Veterinary Ophthalmology as well as to Guide Dogs for the Blind.



Eye Care for Animals board certified ophthalmologists examined more than 200 service dogs in the month of May during the ACVO National Service Dog Free Exam Month.

Congratulations!



Dr. Jason Clark



Dr. Lynsey Smith



Dr. Amy Treadwell

For completing their residency in Comparative Ophthalmology

UPCOMING CONTINUING EDUCATION LECTURES

**Albuquerque, New Mexico
August 21 & 22, 2010**

**4th Annual
Weekend with the Specialists**

*Embassy Suites Hotel & Spa
1000 Woodward Place North East
Albuquerque, New Mexico 87102*

**Tempe, Arizona
November 13, 2010**

A Day with the Specialists

*Fiesta Resort Conference Center
2100 South Priest Drive
Tempe, AZ 85282*

**Culver City, California
August 25, 2010**

**Corneal Ulcerations -
When to Treat and When to Turf**

*City of Angels Veterinary Center
9599 Jefferson Blvd.
Culver City, California 90232*

NEW ECFA LOCATION

Louisville, Kentucky

11800 Capital Way
Louisville, KY 40299
Phone: 502-272-4340
Fax: 502-272-4341
Toll Free: 888-393-4043

Please contact Julie Gamarano for further information at 480-682-6911
jgamarano@eyecareforanimals.com

CERF CORNER



Steve Sisler
DVM, DACVO
Eye Care for Animals

Inherited Retinal Diseases

Our clients often joke with us saying: “How are we going to get their dogs to read the eye chart.” Usually this is followed by a laugh and a quip about “two barks for a bone, one bark for a cat.” Vision testing in our canine companions can provide some humorous material, but the serious reality is that it can be very difficult for owners to recognize subtle vision problems in their pets. Often, it takes severe retinal disease to manifest obvious clinical symptoms of visual impairment. Fortunately, a thorough, dilated retinal exam, such as those performed at CERF examinations, can provide critical and timely information on subtle retinal changes that may lead to progressive visual impairment. Retinal abnormalities found at these examinations may also allow us to intervene in a breeding line that could produce blinding disease multiple generations later.

When a dog is dilated for a CERF exam it is possible to examine the entire 360 degrees of the retina and notice subtle abnormalities. Some of the more common findings include retinal folds, geographic retinal dysplasia, progressive retinal atrophy and early retinal detachments.

Retinal folds, which are created by a folding of multiple layers of the retina, may result in minor or no visual deficits for the patient. However, caution may be advised when breeding some dogs with this particular retinal abnormality as it can be an inherited trait.

Geographical retinal dysplasia affects a larger portion of the retina and it is generally understood there is some degree of visual impairment. Typically, an area in the dorsal retina is affected, and we find this particular genetic abnormality to be more common in English Springer Spaniels and Labrador Retrievers. In the Labradors, this retinal lesion can be associated with a marked varus deformation of the forelimbs and hip dysplasia in a complex referred to as oculoskeletal dysplasia. Dogs with this level of retinal dysplasia definitely should not be used in a breeding program.

Progressive retinal atrophy is a blinding disease that affects many common breeds. While early symptoms can be observed by the owner as vision difficulties in dark environments, physical retinal changes are often able to be detected prior to this point. Typically, a dilated, fundus exam will demonstrate tapetal hyperreflectivity and mild to moderate vascular attenuation. PRA is a bilateral disease; the changes are generally uniform across all portions of the retina, although subtle breed variations do exist. Discovering this problem in a young to middle age breeding dog on a CERF exam, while disappointing, can spare an owner the expense and effort of continuing a line that is destined for serious, blinding ocular disease.

Routine retinal screening can also reveal serious problems that may be treatable. Partial retinal detachments fall into this category and may sometimes have genetic implications for the line. Retinal detachments typically start as small tears in the peripheral retina only visible with extreme care on a dilated exam. Surgery may be performed to correct the tear and preventative steps can be taken to help prevent detachment in the contralateral eye as well.

Many inherited retinal diseases in dogs can go unnoticed by owners as the visual changes can be mild. Routine CERF examinations provide valuable insight into devastating ocular conditions that may go unnoticed at early stages by even the most astute owner.

Check us out at www.eyecareforanimals.com

MEMO TO MANAGERS

Sometimes Offering Praise Is Harder Than It Should Be!

In a busy and growing workplace environment sometimes offering praise is harder than it should be. When schedules are tight and you have a multitude of irons in the fire it's easy to forget to compliment and voice your appreciation to a member of your team. Yet, offering recognition in the form of praise can really make a team member's day. If it has been awhile since you have taken the time to praise a well-deserving team member, consider doing it today.

Provided below are 13 ways to quickly say, "well done"!

1. *Your hard work does not go unnoticed!*
2. *Super effort—you make us all look good.*
3. *Your client service skills are sensational.*
4. *Congratulations on a job well done.*
5. *We are fortunate having you on our team.*
6. *Your perseverance is admirable.*
7. *Your positive energy really lifts the team's spirit!*
8. *You continue to improve—well done.*
9. *The rest of the team appreciates your help, thank you.*
10. *You have grasped the concept well—good job.*
11. *Clients are really noticing the extra efforts you are putting forth.*
12. *What you just did was so helpful, thanks very much.*
13. *You rock—thanks for going above and beyond.*

A 5-second "pat on the back" through verbal recognition can really set the tone of the day with members of your team. It doesn't cost you anything and the positive outcome can go a long way, even spill over to others. Even somewhat struggling team members need to hear some positive, uplifting praise from time to time to encourage them to continue to improve.



Karen Webster, MBA
Chief Operations Officer
Eye Care for Animals

Six Eye Care for Animals

Avondale, Arizona • Gilbert, Arizona • Phoenix, Arizona • Scottsdale, Arizona • Tucson, Arizona • Chula Vista, California • Corte Madera, California
Culver City, California • Palm Desert, California • Pasadena, California • San Diego, California • Santa Rosa, California • Tustin, California
Upland, California • Chicago, Illinois • St. Charles, Illinois • Wheeling, Illinois • Overland Park, Kansas • Louisville, Kentucky
Annapolis, Maryland • Las Vegas, Nevada • Albuquerque, New Mexico • Santa Fe, New Mexico • Akron, Ohio • Austin, Texas
El Paso, Texas • Houston, Texas • Salt Lake City, Utah • Sunset, Utah • Leesburg, Virginia • Pewaukee, Wisconsin

Seeing life through your pet's eyes

FOR ANIMALS



PERMIT #2069
FT WORTH TX
PAID
US POSTAGE
STANDARD
PRESORTED